

# Noninvasive intracranial pressure involving real-time waveform analysis in a child undergoing general anesthesia: a case report

Gabriela Saba<sup>1</sup> , Thaís Condé<sup>1</sup>, Vinícius Quintão<sup>1,2</sup> , Gustavo Vilela<sup>3</sup> ,  
Ricardo Carlos<sup>1,2</sup>, Maria Carmona<sup>1</sup> 

**How to cite:** Saba G, Condé T, Quintão V, Vilela G, Carlos R, Carmona M. Noninvasive intracranial pressure involving real-time waveform analysis in a child undergoing general anesthesia: a case report. *Periop. Anesth. Rep.* 2023;1:e000223. <https://doi.org/10.61724/par.000223>

## ABSTRACT

During neurosurgeries, intracranial pressure (ICP) is usually measured via an intraventricular, intraparenchymal, or subarachnoid catheter. However, the perioperative measurement of ICP is indicated in many circumstances, such as during surgeries performed in the Trendelenburg position. Standard noninvasive techniques, such as computed tomography and optic nerve sheath ultrasound, which give indirect ICP measurements, are usually inaccurate and unavailable during the perioperative period. A new noninvasive intracranial pressure (nICP) monitor (brain4care™, São Paulo, Brazil) measures small skull deformations and precise real-time analysis of ICP. Moreover, brain4care™ is easy to use and free of complications.

## KEYWORDS

Case report; child; intracranial pressure; noninvasive

## INTRODUCTION

Intracranial pressure (ICP) can be precisely measured by an intraventricular, intraparenchymal, or subarachnoid catheter introduced by the neurosurgeon. Usually, catheters are inserted and ICP is monitored during intracranial tumor surgeries or severe traumatic brain injuries. However, noninvasive ICP (nICP) monitoring methods, such as optic nerve sheath ultrasound, computed tomography, Doppler ultrasound, and magnetic resonance imaging, can be used only to infer ICP<sup>(1)</sup>. In addition to inaccuracy, these methods are rarely available in the operating room, and reliance on these methods can lead to inappropriate treatment<sup>(2)</sup>.

Many factors affect ICP during anesthesia, such as whether the patient is in the Trendelenburg position and the presence of pneumoperitoneum, both reducing the cerebral venous return and leading to brain vascular congestion that might increase the ICP<sup>(3)</sup>. Other relevant factors involve alveolar pressure (affecting the venous return), excessive use of intravenous anesthetics (decreasing cerebral metabolic rate of oxygen and blood flow), excessive use of inhalation anesthetics (causing cerebral vasodilation), the presence of hypotension (masking an increase in ICP), end-tidal CO<sub>2</sub> (ETCO<sub>2</sub>) (affecting cerebral vasodilation), hypothermia (which

<sup>1</sup> Universidade de São Paulo, Faculdade de Medicina, São Paulo, Brazil

<sup>2</sup> Universidade de São Paulo, Faculdade de Medicina, Hospital das Clínicas, Instituto da Criança e do Adolescente, São Paulo, Brazil

<sup>3</sup> brain4care™ Scientific Department, São Paulo, Brazil



has the same effect as the excessive use of intravenous anesthetics), and hypervolemia (which can increase cerebral blood flow).

ICP waveforms typically consist of 3 peaks: P1, which is related to the systolic blood pressure transferred by the choroid plexus to the cerebrospinal fluid; P2, which reflects the systolic wave in the parenchymal tissue; and P3, which is affected by aortic valve closure<sup>(1,4)</sup>.

A new nICP sensor and monitor (brain4care™, São Paulo, Brazil) measures small skull deformations non-invasively via a sensor placed on the skin over the temporal bone; the sensor provides real-time intracranial pressure wave data (P1 and P2 curves morphologies), and the anesthesiologist can determine whether intracranial compliance has been preserved<sup>(2,5)</sup>. This monitor (brain4care™, São Paulo, Brazil) is innovative because it delivers accurate measurements of intracranial compliance without inserting an invasive catheter<sup>(5)</sup>.

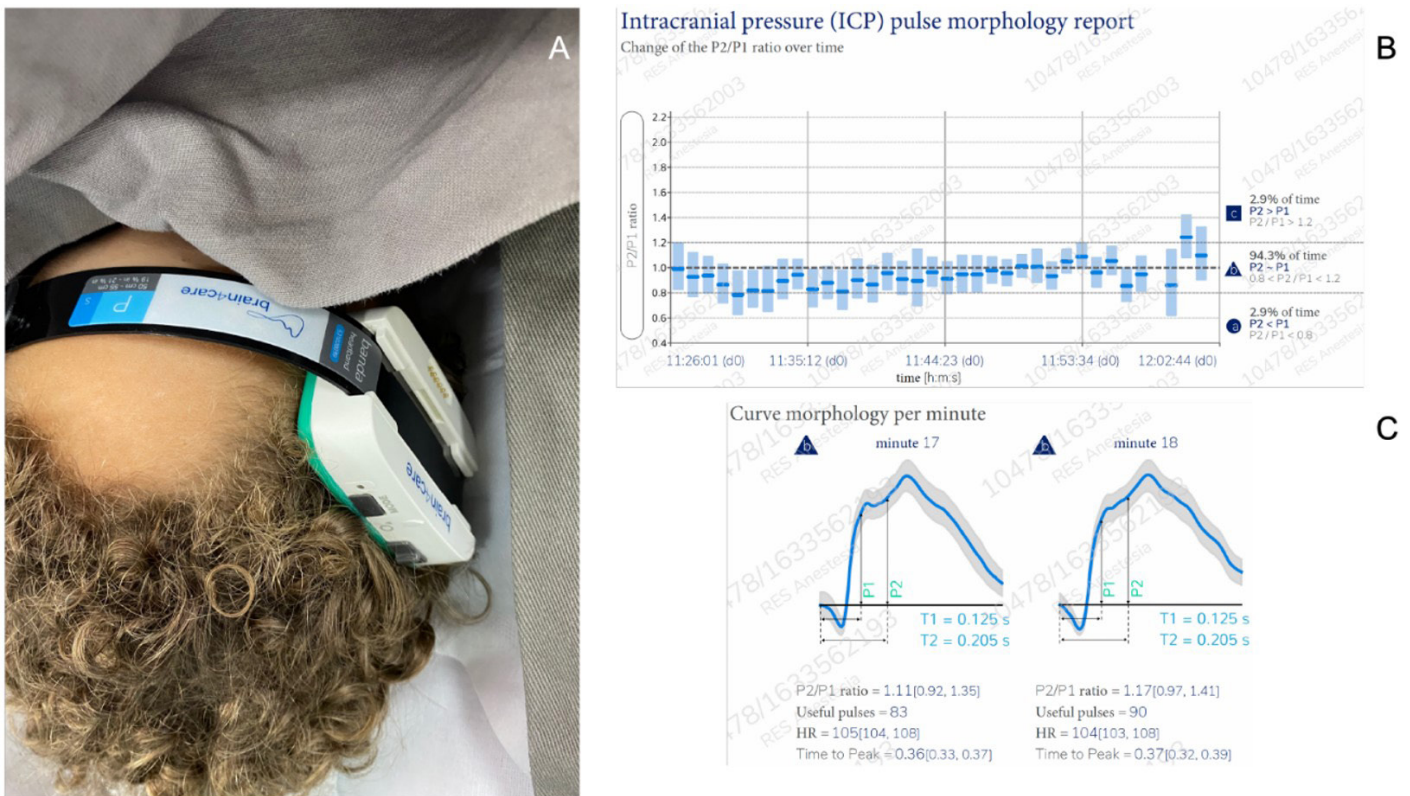
We report using an nICP monitor (brain4care™, São Paulo, Brazil) in a child who underwent an operation with his head slightly below the horizontal plane and had no other factors associated with increased ICP. Written and informed consent was obtained from the patient's mother to publish this Case Report. This case has been reported according to the Anesthesia Case REport (ACRE)<sup>(6)</sup> checklist and CARE (CAse REport) statement<sup>(7)</sup>.

## CASE DESCRIPTION

We report a case involving a 1-year-old boy (9.6 kg) with American Society of Anesthesiologists physical status I who underwent circumcision and bilateral open orchiopexy. The child was monitored with a noninvasive blood pressure monitoring device, EKG, pulse oximeter, esophageal thermometer, and a nICP monitor (brain4care™, São Paulo, Brazil) (Figure 1A).

After the induction of anesthesia with sevoflurane via an inhalation mask and the placement of an i.v. catheter, intravenous anesthesia induction was performed with propofol 1 mg.kg<sup>-1</sup>, fentanyl 2 mcg.kg<sup>-1</sup>, and cisatracurium 0.15 mg.kg<sup>-1</sup>. After orotracheal intubation, anesthesia was maintained with sevoflurane (2-3%). A sacral block was performed with 10 mL of ropivacaine 0.2%. During surgery, the child was supine, the table tilted 16 degrees, and his head was below the horizontal plane. The child received a total of 50 mL of Ringer's lactate solution. During the perioperative period, his temperature was between 35.8 and 36.6 °C, peak pulmonary pressure was 15 cmH<sub>2</sub>O, PEEP was 5 cmH<sub>2</sub>O, and ETCO<sub>2</sub> was 34-35 mmHg.

We consider a P2/P1 ratio between 1.0 and 1.2 in the warning zone regarding a change in intracranial compliance<sup>(5,8)</sup>. A P2/P1 ratio greater than 1.2 is in the red zone concerning a change in intracranial compliance<sup>(5,8)</sup>. We also analyzed



**Figure 1. A** – Child monitored with the brain4care™ pediatric sensor; **B** – Chart showing the trend in the P2/P1 ratio throughout the procedure; **C** – ICP morphology at minutes 17 and 18 showed a P2/P1 ratio higher than 1.2 and a time to peak higher than 0.25. HR: heart rate; ICP: intracranial pressure.

the time to peak, which is the time from the start to the highest point of the curve. This time is mathematically normalized according to the heart rate. An abnormal pulse may indicate lower intracranial compliance, generating pyramidal curves and a longer time to peak. Values greater than 25% are a cause for concern<sup>(5,8)</sup>.

The ICP curves showed modifications suggesting worsening intracranial compliance during surgery (Figure 1B-1C). In fact, at approximately 3% of the surgery duration, after the patient was placed in the Trendelenburg position, the P2/P1 ratio was greater than 1.2. To compare the variations in intracranial compliance measured via different methods, optic nerve ultrasound (ONSD) was performed every 10 minutes. The values were kept between 3.6 and 5.7 mm, considered typical values for this child<sup>(9)</sup>. The procedure lasted 90 minutes, and the child was extubated when placed in the horizontal position and transferred to the recovery room without complications.

## DISCUSSION

This noninvasive intracranial compliance monitor (brain4care™, São Paulo, Brazil) consists of a mechanical extensometer that measures pressure and is affixed to automatic equipment that contacts the patient's scalp, enabling the detection of small skull deformations resulting from changes in ICP<sup>(2,5)</sup>. Although this method is limited because it does not deliver values in millimeters of mercury, it can yield continuous real-time information about the ICP waves that is immediately processed by the software and available to the user<sup>(5,10)</sup>.

The P1 and P2 peak amplitudes are directly related to intracranial compliance. If the P2 peak is higher than the P1 peak, it suggests worsening intracranial compliance<sup>(5,11)</sup>. Therefore, this monitor can provide a relatively accurate picture of intracranial compliance by analyzing ICP curves.

In this case report, the analysis of the ICP waves showed a change in intracranial compliance as soon as the patient was placed in the surgical position and returned to the baseline value after 15 minutes. Comparatively, the optic nerve sheath measurements were the same 1 hour after the patient was placed in the surgical position. This might indicate that the sensitivity of ONSD is inadequate for diagnosing changes in intracranial compliance during the perioperative period. In addition, ONSD depends on the individual operator, and can negatively influence the early performance of anesthesiologists.

Studies involving more participants are necessary to verify the importance of transient increases in ICP and related clinical outcomes. However, noninvasive devices, such as this novel nICP (brain4care™, São Paulo, Brazil), are potentially beneficial to anesthesiologists because

they do not harm the patient, are easy to operate, including real-time analysis software and are more accurate than current bedside alternatives. Additional suggested studies include cerebral oximetry to assess the effects of these interventions in balancing oxygen supply and consumption and analyzing brain tissue perfusion.

We suggest improving perioperative intracranial pressure monitoring because of relevant changes in intracranial compliance during surgeries. Additionally, exploratory use of these novel noninvasive technologies to monitor ICP is strongly needed.

## ACKNOWLEDGEMENTS

The authors thank the Scientific Department of brain4care™ for constructing the pediatric sensors and monitors available, enabling us to generate this case report.

## REFERENCES

1. Fan JY, Kirkness C, Vicini P, Burr R, Mitchell P. Intracranial pressure waveform morphology and intracranial adaptive capacity. *Am J Crit Care*. 2008;17(6):545-54. <http://dx.doi.org/10.4037/ajcc2008.17.6.545>. PMID:18978239.
2. Vilela GH, Cabella B, Mascarenhas S, Czosnyka M, Smielewski P, Dias C, et al. Validation of a new minimally invasive intracranial pressure monitoring method by direct comparison with an invasive technique. *Acta Neurochir Suppl*. 2016;122:97-100. [http://dx.doi.org/10.1007/978-3-319-22533-3\\_19](http://dx.doi.org/10.1007/978-3-319-22533-3_19). PMID:27165885.
3. Rosenthal RJ, Hiatt JR, Phillips EH, Hewitt W, Demetriou AA, Grode M. Intracranial pressure. Effects of pneumoperitoneum in a large-animal model. *Surg Endosc*. 1997;11(4):376-80. <http://dx.doi.org/10.1007/s004649900367>. PMID:9094281.
4. Dias C, Maia I, Cerejo A, Varsos G, Smielewski P, Paiva JÁ, et al. Pressures, flow, and brain oxygenation during plateau waves of intracranial pressure. *Neurocrit Care*. 2014;21(1):124-32. <http://dx.doi.org/10.1007/s12028-013-9918-y>. PMID:24072460.
5. Frigieri G, Andrade RAP, Dias C, Spavieri DL Jr, Brunelli R, Cardim DA, et al. Analysis of a non-invasive intracranial pressure monitoring method in patients with traumatic brain injury. *Acta Neurochir Suppl*. 2018;126:107-10. [http://dx.doi.org/10.1007/978-3-319-65798-1\\_23](http://dx.doi.org/10.1007/978-3-319-65798-1_23). PMID:29492543.
6. Shelton CL, Klein AA, Bailey CR, El-Boghdadly K. The Anaesthesia Case Report (ACRE) checklist: a tool to promote high-quality reporting of cases in peri-operative practice. *Anaesthesia*. 2021;76(8):1077-81. <http://dx.doi.org/10.1111/anae.15391>. PMID:33440026.
7. Riley DS, Barber MS, Kienle GS, Aronson JK, von Schoen-Angerer T, Tugwell P, et al. CARE guidelines for case reports: explanation and elaboration document. *J Clin Epidemiol*. 2017;89:218-35. <http://dx.doi.org/10.1016/j.jclinepi.2017.04.026>. PMID:28529185.

8. Ballesterio MFM, Frigieri G, Cabella BCT, Oliveira SM, Oliveira RS. Prediction of intracranial hypertension through noninvasive intracranial pressure waveform analysis in pediatric hydrocephalus. *Childs Nerv Syst.* 2017;33(9):1517-24. <http://dx.doi.org/10.1007/s00381-017-3475-1>. PMID:28623520.
9. Lashutka MK, Chandra A, Murray HN, Phillips GS, Hiestand BC. The relationship of intraocular pressure to intracranial pressure. *Ann Emerg Med.* 2004;43(5):585-91. <http://dx.doi.org/10.1016/j.annemergmed.2003.12.006>. PMID:15111918.
10. Mascarenhas S, Vilela GH, Carlotti C, Damiano LE, Seluque W, Colli B, et al. The new ICP minimally invasive method shows that the Monro-Kellie doctrine is not valid. *Acta Neurochir Suppl.* 2012;114:117-20. [http://dx.doi.org/10.1007/978-3-7091-0956-4\\_21](http://dx.doi.org/10.1007/978-3-7091-0956-4_21). PMID:22327675.
11. Saba GT, Quintão VC, Zeferino SP, Simões CM, Coelho RF, Fazoli A, et al. Noninvasive intracranial pressure real-time waveform analysis monitor during prostatectomy robotic surgery and Trendelenburg position: case report. *Braz J Anesthesiol.* 2021;71(6):656-9. <http://dx.doi.org/10.1016/j.bjane.2021.09.003>. PMID:34606786.

**This study was carried out at the Instituto da Criança e do Adolescente, Hospital das Clínicas, Faculdade de Medicina, Universidade de São Paulo.**

**Authors' contributions:** Ricardo Carlos, Gabriela Saba, and Gustavo Vilela helped conceptualize and design the case report and drafted the manuscript in its entirety. Vinícius Quintão, Thaís Condé, Maria Carmona, and Ricardo Carlos helped draft the manuscript in its entirety and reviewed and critically revised the manuscript. All authors reviewed and critically revised the manuscript and approved the final manuscript.

**Ethics statement:** Written and informed consent was obtained from the patient's mother for the publication of this Case Report.

**Conflict of interest:** Gustavo Vilela is the scientific director of brain4care™. Gabriela Saba, Thaís Condé, Vinícius Quintão, Ricardo Carlos, and Maria Carmona have no conflicts of interest to disclose.

**Financial support:** None.

**Submitted on:** January 26<sup>th</sup>, 2023

**Accepted on:** March 17<sup>th</sup>, 2023

**Correspondence:**

Vinícius Quintão

Universidade de São Paulo, Faculdade de Medicina, Hospital das Clínicas, Divisão de Anestesia

155 Av. Dr. Enéas Carvalho de Aguiar, Prédio dos Ambulatórios, 8º andar, Cerqueira César, São Paulo, SP, Brasil

Phone: +55 11 2661-6335

[vinicius.quintao@hc.fm.usp.br](mailto:vinicius.quintao@hc.fm.usp.br)