




# Challenges in determining the right endotracheal tube during anesthesia. Case report and literature review

Anderson José Gonçalves<sup>1</sup> , Paula Lima Antoniazzi<sup>1</sup> , Paulo Sérgio Mateus Marcelino Serzedo<sup>1</sup> 

**How to cite:** Gonçalves AJ, Antoniazzi PL, Serzedo PSMM. Challenges in determining the right endotracheal tube during anesthesia. Case report and literature review. *Periop. Anesth. Rep.* 2024;2:e000524. <https://doi.org/10.61724/par.000524>

## ABSTRACT

The gold standard for securing and accessing the airways under anesthesia is orotracheal intubation. The selection of the endotracheal tube is empirical and depends on the age and sex of the patient. A 59-year-old patient underwent oncologic surgery. After induction, the patient was intubated by direct laryngoscopy and no problems were noted during the procedure. During repositioning, the patient experienced a refractory episode of desaturation. A chest X-ray revealed selective right bronchus intubation and total opacification of the left lung. After repositioning the endotracheal tube, the radiograph showed complete resolution of the left lung atelectasis and no further anesthetic problems. Selective intubation, barotrauma, respiratory failure, and laryngotracheal mucosa injury can all result from poor endotracheal tube selection. Consequently, anesthesiologists must exercise caution when selecting an endotracheal tube to ensure optimal airway control.

## KEYWORDS

Intubation; tracheal; endotracheal intubation; case report

## INTRODUCTION

Orotracheal intubation (OIT) is the gold standard for accessing and securing the airways during surgical procedures. Although specific formulas have been given in the literature, most physicians carry out OIT based on practical experience rather than formulas.

Despite significant anatomical heterogeneity, the patient's age and gender are used to select an endotracheal tube (ETT), which can lead to fatal complications<sup>(1)</sup>. The following describes a case of OIT achieved with an empirically selected tube based on the patient's height and a review of the literature on OIT to reduce and prevent intra- and post-operative problems associated with it.

## CASE DESCRIPTION

A 59-year-old female, 1.50m, 65kg, body mass index (BMI): 28.9 kg/m<sup>2</sup>, American Society of Anesthesiologists (ASA) III, had a history of rectosigmoidal tumor and underwent an oncologic rectosigmoidectomy with videolaparoscopic lymphadenectomy under total intravenous general anesthesia. After induction, the patient was intubated by single direct laryngoscopy, Cormack-Lehane I classification, with insertion of endotracheal tube (ETT) size 7.5, until the mark "21.5" printed in the ETT reached the teeth line, with cuff insufflation of 10 mmHg. No further problems were reported during intubation. After positioning the patient in the lithotomy position, the patient had a refractory episode of desaturation reaching

<sup>1</sup>Santa Casa de Misericórdia de Ribeirão Preto, Department of Anesthesiology, Ribeirão Preto, SP, Brazil



87% on plethysmography, with a concomitant decrease in quantitative end-tidal carbon dioxide (ETCO<sub>2</sub>).

In the event of an air leak, the ETT was replaced with a similar one with a tooth line of "20", persistent hypoventilation, and complete cessation of pulmonary auscultation of the left lung. The anesthesia team then suspected selective right lung intubation and performed a chest image (Figure 1), which revealed complete opacification of the left lung, carina just below the suprasternal notch, and selective intubation of the right bronchus. The ETT was subsequently advanced to mark "18", resulting in improved ventilatory parameters. A new X-ray revealed complete eradication of left lung atelectasis (Figure 2).

The surgical treatment and extubation of the patient proceeded without further anesthetic difficulties, and the patient was discharged two days after surgery with no cardiopulmonary complications.

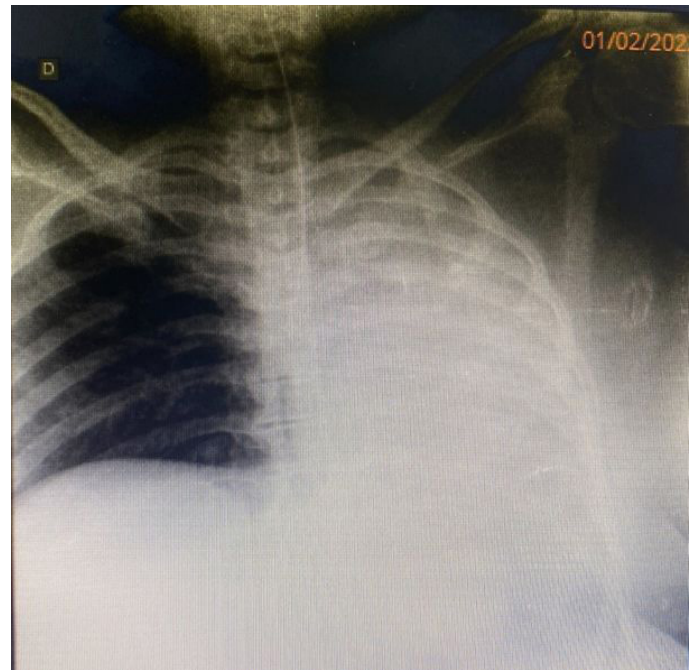
## DISCUSSION

OIT is a medical procedure commonly used to gain access to the airway. It is potentially life-saving, especially in emergency situations, and is considered the gold standard in airway management<sup>(2)</sup>. On the other hand, unlike pediatric and thoracic anesthesia<sup>(1)</sup>, there are no standards to determine the appropriate ETT size for adult surgical patients, which can pose a significant problem for anesthesiologists<sup>(3)</sup>, who must ensure adequate airway patency during elective and emergency procedures<sup>(4)</sup>.

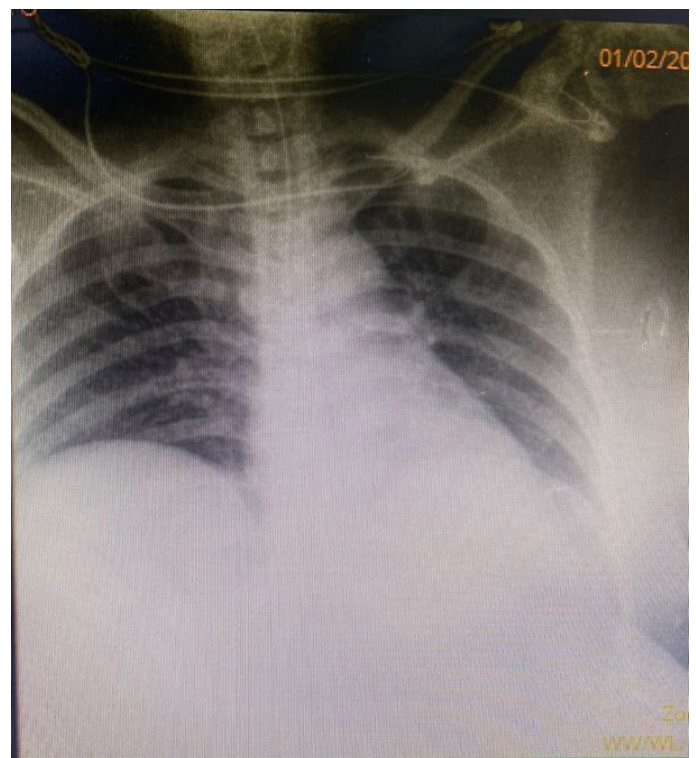
Selecting an appropriate ETT size is difficult because the anesthesiologist must consider several variables, including airway management, esophageal intubation<sup>(5)</sup>, direct lesions of the pharynx and larynx<sup>(6)</sup>, tracheal stenosis<sup>(5)</sup>, hypotension, and cardiac arrest<sup>(5,6)</sup>.

The difficulty in systematizing guidelines can be attributed to the sizeable anatomical heterogeneity of airway structures<sup>(7)</sup>. Some studies demonstrated that the length of the trachea oscillates between 10 to 15 cm, with a diameter of 4 mm in neonates and 18 mm in adults<sup>(2)</sup>. After reaching the carina, it divides into the main bronchi and enters the lungs, with a large variability in tracheal dimensions between subjects of the same population in cadaveric studies<sup>(3)</sup>.

Thus, selecting the right size of ETT during OIT is imperative because airway structures are complex and delicate. A mistake in choosing the best tracheal tube can lead to complications, as demonstrated by Karmali and Rose<sup>(1)</sup> that a large tracheal tube imposes contact pressures in some tracheal points that can reach up to 200 mmHg, leading to ischemia and increasing morbid



**Figure 1.** Selective right lung intubation, with atelectasis left lung.



**Figure 2.** X-ray after the replacement of the ETT.

mortality. Some studies have shown that ETT malposition is not uncommon, occurring in 14-61% of patients<sup>(6)</sup>.

The specific literature is controversial, with some studies recommending the insertion of the largest ETT based on the patient's height and gender, while others found no association between the length and diameter of airway

structures and patient height<sup>(4)</sup>. This discrepancy may result in local trauma, multiple intubation attempts, tube misplacement, unnecessary tube changes, or selective lung intubation with an incidence of up to 12%<sup>(5)</sup>.

However, recent research using computed tomography (CT) and linear regression models has shown a strong correlation between tracheal diameter and height<sup>(3)</sup>. While body weight has been shown not to correlate with airway size, height is associated with tracheal dimensions. In addition, tracheal size and BMI are inversely correlated<sup>(1)</sup>, and are associated with increased risk during airway management.

Additionally, choosing the proper ETT placement depth is fundamental to the anesthetic procedure<sup>(1,2)</sup>. Nonetheless, the most common complication is selective intubation of the right main bronchus, which can arise in as many as 8% of intubations which can occur in up to 8% of intubations and can cause severe lung injury to the intubated lung, atelectasis of the contralateral lung, and, ultimately, respiratory failure<sup>(5)</sup>.

Since Sintavanuruk's formula<sup>(8)</sup> was used to determine the depth of insertion of the ETT in this instance, it can be noted that these formulas are not a reliable indicator of the depth of insertion of the ETT. The ideal method to confirm that the ETT is in the "right place," as mentioned by Ahn et al.<sup>(9)</sup> is to use clinical signals, such as equal breath sounds, capnography waveforms, and ET<sub>CO</sub><sub>2</sub> values<sup>(10)</sup>. More recently, point-of-care ultrasound (POCUS) and ultrasound measurements are accurate and repeatable measurement methods<sup>(5)</sup>.

Selective intubation, barotrauma, respiratory failure, injury to the vocal cords, laryngotracheal mucosa with pressures exceeding 200 mmHg, and more can result from improper ETT selection, with females more likely to be impacted than males. As a result, anesthesiologists need to be cautious in selecting the smaller ETT size that can provide the best ventilation and oxygenation without causing lesions to the specific tissues of the airways<sup>(1)</sup>, and refrain from practice or pragmatism when considering ETT, as indicated in this case report. Moreover, it is difficult to accurately determine the dimensions of the airways by observation alone.

## REFERENCES

1. Karmali S, Rose P. Tracheal tube size in adults undergoing elective surgery - a narrative review. *Anaesthesia*. 2020;75(11):1529-39. <http://doi.org/10.1111/anae.15041>. PMID:32415788.
2. Hagberg CA, Artime CA, Gonçalves AJ, Antoniazzi PL, Serzedo PSMM. Manejo das vias aéreas no adulto. In: autor. *Miller's Anesthesia*. 8th ed. London, United Kingdom: Churchill Livingstone; 2019. p. 4846-4958.
3. Cao AC, Rereddy S, Mirza N. Current practices in endotracheal tube size selection for adults. *Laryngoscope*. 2021;131(9):1967-71. <http://doi.org/10.1002/lary.29192>. PMID:33118621.
4. Ideris SS, Che Hassan MR, Abdul Rahman MR, Ooi JS. Selection of an appropriate left-sided double-lumen tube size for one-lung ventilation among Asians. *Ann Card Anaesth*. 2017;20(1):28-32. <http://doi.org/10.4103/0971-9784.197824>. PMID:28074791.
5. Gottlieb M, Holladay D, Burns KM, Nakitende D, Bailitz J. Ultrasound for airway management: an evidence-based review for the emergency clinician. *Am J Emerg Med*. 2020;38(5):1007-13. <http://doi.org/10.1016/j.ajem.2019.12.019>. PMID:31843325.
6. Oliveira ACM, Friche AAL, Salomão MS, Bougo GC, Vicente LCC. Predictive factors for oropharyngeal dysphagia after prolonged orotracheal intubation. *Rev Bras Otorrinolaringol*. 2018;84(6):722-8. <http://doi.org/10.1016/j.bjorl.2017.08.010>. PMID:28951127.
7. D'Anza B, Knight J, Greene JS. Does body mass index predict tracheal airway size? *Laryngoscope*. 2015;125(5):1093-7. <http://doi.org/10.1002/lary.24943>. PMID:25251641.
8. Sintavanuruk K, Rodanant O, Kositanurit I, Akavipat P, Pulnitiporn A, Sriraj W. The Thai Anesthesia Incident Monitoring Study (Thai AIMS) of endobronchial intubation: an analysis of 1996 incident reports. *J Med Assoc Thai*. 2008;91(12):1854-60. PMID:19133520.
9. Ahn JH, Park JH, Kim MS, Kang HC, Kim IS. Point of care airway ultrasound to select tracheal tube and determine insertion depth in cleft repair surgery. *Sci Rep*. 2021;11(1):4743. <http://doi.org/10.1038/s41598-021-84297-4>. PMID:33637826.
10. Silvestri S, Ladde JG, Brown JF, et al. Endotracheal tube placement confirmation: 100% sensitivity and specificity with sustained four-phase capnographic waveforms in a cadaveric experimental model. *Resuscitation*. 2017;115:192-8. <http://doi.org/10.1016/j.resuscitation.2017.01.002>. PMID:28111195.

**The study was carried out at the Department of Anesthesiology, Santa Casa de Misericórdia de Ribeirão Preto, São Paulo, Brazil**

**Authors' contributions:** Conception: Anderson José Gonçalves, Paulo Sérgio Mateus Marcelino Serzedo. Design: Anderson José Gonçalves, Paulo Sérgio Mateus Marcelino Serzedo. Patient examination: Anderson José Gonçalves, Paula Lima Antoniazzi. Writing-, review- and editing-: Anderson José Gonçalves, Paula Lima Antoniazzi, Paulo Sérgio Mateus Marcelino Serzedo. All the authors have edited and approved the contents of the manuscript.

**Ethics statement:** The patient roled in this case provided informed consent, and the study design was approved by the appropriate ethics review board, registered under number 6.667.415, and was conducted according to the principles

expressed in Declaration of Helsinki.

Conflict of interest: none

Financial support: none

Submitted on: April 4th, 2024

Accepted on: June 19th, 2024

Correspondence

Anderson José Gonçalves

Santa Casa de Misericórdia de Ribeirão Preto, Department of Anesthesiology

456 Av. Saudade, Campos Elíseos, Ribeirão Preto, SP, Brazil

Phone: +55 (16) 3605-0606

anderson-goncalves@hotmail.de